KERECIS

Distributed by:
PMI PolyMedics Innovations Inc.

Application of **KERECIS** in different indications

Scientific Update 02/2018

ABA Annual Meeting 2018

- special edition -

- Comparison of Omega-3 Rich Fish Skin Dermis and Fetal Bovine Dermis on Deep Partial Thickness Burns
- Omega-3 Rich Fish Skin Grafts Reduce Donor Skin Requirements for Full Thickness Burns
- Fish Skin Grafts Support Ingrowthand Colonization of Adipose Derived Stem Cells in Vitro
- Omega-3 rich Fish Skin Grafts in the Treatment of Full Thickness Burns: A Comparative Trial of Fish Skin and Cadaver Skin in a Porcine Model

KERECIS Newsletter

Welcome

KERECIS received significant attention at the ABA 50th Annual Meeting in Chichago this month with 2 oral and 3 Poster presentations.

The presentations showed based on new animal data that

- Kerecis integrates faster than Primatrix allowing for STSG coverage at day 14 vs. day 21
- There were no differences in contracture rates between Kerecis and Primatrix
- Kerecis treated wounds showed no infections
- Kerecis can be used as a temporary cover replacing cadaver skin with similar outcomes
- Kerecis reduces the need for autografting
- Kerecis supports ingrowth and colonization of adipose derived stem cells

We thank all presenters for their contributions to better understanding when and how **KERECIS** can be used in the clinical practice and hope you will attend at our next **KERECIS** User Workshop!

If you have any questions about KERECIS, please feel free to contact me or our team. We will do whatever we can to make sure your patients will receive the best treatment.

Thank you!
Christian Planck
Chief Operating Officer

Comparison of Omega-3 Rich Fish Skin Dermis and Fetal Bovine Dermis on Deep Partial Thickness Burns

R Stone, II, PhD, D Larson, MS, J Wall, BS, K Florell, BS, H Dillon, BS ...

Journal of Burn Care & Research, Volume 39, Issue suppl_1, 9 April 2018, Pages S156,
More information

Published: 09 April 2018

Abstract

Introduction

Thermal injuries can be caused by exposure to a wide variety of sources including heat, electricity, radiation, chemical agents, and friction. Split thickness skin grafts are currently the gold standard, which are not only associated with donor site morbidity, they may be impossible in cases where there is no available donor skin. The paucity of donor sites in patients with burns involving large total body surface areas highlights the need for better cellular and tissue-based products (CTPs) that can achieve early and complete coverage while retaining normal skin function. A variety of CTPs have been tested on burn wounds resulting in limited success due to poor integration and insufficient revascularization of the product. The purpose of this preclinical trial was to evaluate CTPs sourced from two different animals on deep partial thickness (DPT) burn wounds.

Methods

Twenty four DPT 5x5 cm burn wounds were created on the dorsum of six anesthetized Yorkshire pigs using appropriate pain control methods. Wounds were excised down to a bleeding wound bed after 24 hours and treated with omega-3 rich fish skin dermis or fetal bovine dermis. A reapplication of the fish skin dermis was applied after 7 days and all wounds were allowed to heal by secondary intentions. Rechecks were performed on days 7, 14, 21, 28, 45, and 60 during which digital images, non-invasive measurements, and punch biopsies were acquired. Quantitative measurements include re-epithelialization, contraction rates, transepidermal water loss (TEWL), hydration, and laser speckle.

Results

Both treatments created a granulated wound bed that would have been receptive to a skin graft if desired; however, more fish skin dermis treated wounds were receptive at day 14 while the fetal bovine dermis wounds were not until day 21. The wounds treated with fish skin dermis resulted in faster re-epithelialization (50.2% vs. 23.5% at day 14 and 81.7% vs. 62.3% at day 21, $p<0.001$). No difference in TEWL or contraction rates were observed at days 21, 28, 45, and 60 between the two groups. The fetal bovine dermis took longer to integrate into the wound bed than the fish skin dermis which was evident in higher hydration values at day 21 (2500.4 vs. 309.7 µS, $p<0.0001$) and lower blood flow measured at day 14 via laser speckle (3.3 vs. 5.1 fold change increase over normal skin, $p<0.0001$).

Conclusions

This study describes a treatment option using fish skin dermis that improves burn wound healing over fetal bovine dermis. Our results indicate that fish skin dermis integrated faster and allowed quicker wound closure without any skin grafts while not increasing contraction of burn wounds.

Applicability of Research to Practice

The ultimate aim for this research is to identify CTPs that can improve healing of burn wounds without the need for additional skin grafting.

Omega-3 Rich Fish Skin Grafts Reduce Donor Skin Requirements for Full Thickness Burns

R Stone, II, PhD, D Larson, MS, J Wall, BS, K Florell, BS, H Dillon, BS ...

Journal of Burn Care & Research, Volume 39, Issue suppl_1, 9 April 2018, Pages S234–S235,
More information

Published: 09 April 2018

Abstract

Introduction

Large total body surface area burns pose significant therapeutic challenges. Clinically, the extent and depth of burn injury may mandate the temporary use of cadaver skin (allograft) to protect the wound and allow formation of granulation tissue while split thickness skin grafts (STSG) are serially harvested from the same donor areas. However, allografts are not always available and have high cost associated with them, thus the interest in identifying lower cost, readily available products that serve the same function. A second function of allografts is to protect a highly meshed STSG (mSTSG) from desiccation and shearing. The purpose of this study was to evaluate omega-3 rich fish skin graft (FSG) as a temporary cover to prepare the wound bed for mSTSG application and as protection over a highly meshed STSG.

Methods

Thirty six full thickness (FT) 5x5 cm burn wounds were created on the dorsum of six anesthetized Yorkshire pigs on day -1 using appropriate pain control methods. To mimic the 2 stage clinical situation, on day 0 (D0) wounds were excised down to a bleeding wound bed and a temporary cover was applied, then on day 7 (D7) wounds were debrided to a viable granulated wound bed prior to application of mSTSG. The wounds were evenly divided into three treatment groups: 1) FSG (D0) + 1.5:1 mSTSG (D7); 2) cadaver porcine skin (D0) + 1.5:1 mSTSG (D7); 3) FSG (D0) + 3:1 mSTSG and FSG applied over the graft (D7). Rechecks were performed on days 14, 21, 28, 45, and 60 during which digital images, non-invasive measurements, and punch biopsies were acquired. Quantitative measurements include contraction rates, transepidermal water loss (TEWL), hydration, and laser speckle.

Results

The FSG created a granulated wound bed that was receptive to application of mSTSG. No infection was detected in wounds treated with FSG. FT burn wounds treated with FSG had similar outcome measures (contraction rates, TEWL measurements, hydration levels, and blood perfusion levels) compared to cadaver skin treated burn wounds. The 3:1 mSTSG treated with FSG resulted in similar healing as the wounds treated with the 1.5:1 mSTSG.

Conclusions

FSG performed as well as cadaver skin as a temporary cover. This study shows that the product was not inferior to standard of care. Most importantly, the wounds treated with FSG and 3:1 mSTSG healed similar to all other wounds. This means that half as much graft was necessary to result in similar healing without the meshed pattern that is typically associated with grafts of a higher meshing ratio.

Applicability of Research to Practice

The identification of 'off the shelf' products that can prevent desiccation of the wound and prepare the wound bed for subsequent surgery is of great interest. The aim of this research was to determine if FSG could be used as a temporary cover and if FSG could reduce the needs of autograft.

Fish Skin Grafts Support Ingrowthand Colonization of Adipose Derived Stem Cells in Vitro

S Magnusson, BSc, M McIntyre, BA, D M Burmeister, PhD, R J Christy, PhD, H Kjartansson, MD ...

Journal of Burn Care & Research, Volume 39, Issue suppl_1, 9 April 2018, Pages S63,
More information

Published: 09 April 2018

Abstract

Introduction

The scarcity of donor sites in patients with large burn wounds body highlights the need for more advanced treatments. Many tissue based products have been tested on burn wounds but with limited success due to poor integration and insufficient revascularization of the product. Fish skin grafts (KerecisTM Omega3) are naturally rich in Omega3 polyunsaturated fatty acids (PUFAs), which are precursors of the specialized pro-resolving lipid mediators (SPM) that modulate the immune response, tissue remodeling and of pain. Viral transmission risk is nonexistent from the Atlantic cod (Gadus morhua) preserving the intrinsic structure and biochemical composition. Clinical trials have shown that one such graft (Kerecis™ Omega3) significantly accelerates healing compared to a porcine matrix product. Separately, adipose derived stem cells ("ADSCs") facilitate wound healing by enhancing cell migration and neovascularization, and may be incorporated into different grafts. The objective of this study was to evaluate the ability of fish skin graft to support ingrowth of ADSCs.

Methods

ADSCs and fibroblasts were seeded (50,000 cells/cm2) onto 6 mm biopsy punches of fish skin in a 96 well plates. Growth medium was changed every 2 days, and samples were fixed on days 7, 14, 18 and 21 post-seeding. Samples, 2 µm in thickness were embedded in paraffin and H&E stained. Cell ingrowth was quantified with the ImageJ software. Vertical gridlines of 100 µm increments were created and ingrown cells within each grid counted.

Results

The acellular fish skin graft* supported and sustained three dimensional ingrowth of ADSCs for over 21 days in vitro. The number of ADSCs increased progressively across time and was 3.7 ± 0.6, (n=2) 9.8 ± 1.4 (n=3), 20 ± 2.6 (n=2), 22.4 ± 1.9 (n=3) and 29.4 ± 2.7 (n=2), at days 7, 10, 14, 18, and 21, respectively. Anova showed a significant difference between the groups (p=0,0004). Tukey post hoc testing revealed a significant difference between day 7 and all other points except day 10.

Conclusions

Acellular fish skin supports and sustains three-dimensional ingrowth of ADSCs. Combination products including stem cells and fish skin graft may provide a novel and effective treatment for burn patients.

Applicability of Research to Practice

ADSC based wound treatments are being developed but the best way to administer the ADSCs has not been determined. Fish skin seeded and cultured with autologous ADSCs could provide autologous, and non-immunogenic personalized wound coverage. This dual-action therapy may enhance burn healing via the benefits of the Omega3 derived SPMs and ADSCs.

Omega-3 rich Fish Skin Grafts in the Treatment of Full Thickness Burns: A Comparative Trial of Fish Skin and Cadaver Skin in a Porcine Model

H Kjartansson, MD, S Jeffery, MD, B T Baldursson, MD, PhD, S Magnusson, BSc, S Karason, MD ...

Journal of Burn Care & Research, Volume 39, Issue suppl_1, 9 April 2018, Pages S65,
More information

Published: 09 April 2018

Abstract

Introduction

The management of full thickness burns can include an initial application of cadaver skin or skin substitute followed by split thickness skin grafting (STSG). Non existing disease transmission risk from the Atlantic cod (Gadus morhua) to humans allows for gentler processing of the fish skin (Kerecis TM Omega3) that preserves natural structure and content making the skin more similar to human skin than processed mammalian matrixes. The additional benefits of the pain relieving properties of omega-3 can have significant impact on patients' quality of life.

Methods

To determine the safety and efficacy of acellular fish skin for temporary coverage and autograft sparing in a full thickness porcine burn model. One hundred (100) full thickness burn wounds were produced on the back and flanks of 5 pigs. After debridement, the wounds were randomized; meshed fish skin graft (n=30); intact fish skin graft (n=30); cadaver skin (gold standard, n=20) and regular wound dressing (Allevyn, n= 20). At three and ten days following debridement, the wounds treated with the fish skin and the cadaver skin were grafted with STSG. Half of the fish skin treated wounds were grafted with either a 3:1 meshed or sheet STSG. Punch biopsies were taken for histology.

Results

The fish skin grafts provided good temporary coverage with a granulated wound bed well prepared for STSG. Excellent healing was demonstrated for all wounds treated with the fish skin. No significant wound contracture difference was identified between the cadaver skin group, the STSG sheet grafted group and the group treated with 3:1 meshed STSG with a second application of acellular fish skin graft.

Conclusions

In this model, the fish skin graft demonstrated comparable results with cadaver skin for temporary coverage and augmented healing with a meshed autograft in a 3:1 ratio. The results demonstrate proof of concept for autograft sparing and are proposed to be further evaluated on a larger scale in well validated animal models followed by clinical trials.

Applicability of Research to Practice

The identification of 'off the shelf' products that can prepare the wound bed for subsequent grafting is of great interest. The aim of this research was to determine if fish skin could be used as an alternative to cadaver skin for temporary coverage with good subsequent graft take.

The Use of Omega3 Rich Fish Skin Xenograft in the Treatment of Superficial Burns and Split Thickness Skin Graft Donor Sites

Khurshid Alam[1], Lt Col SLA Jeffery RAMC[2,3]

[1]North Middlesex University Hospital
[2]The Royal Centre for Defence Medicine, The Queen Elizabeth Hospital, Birmingham
[3]Birmingham City University

BIRMINGHAM City University

NHS National Institute for Health Research

University Hospital Birmingham NHS Foundation Trust

Introduction

When treating large burns, autologous skin availability becomes a problem and burn surgeons often rely heavily on allogenic and xenogeneic skin for temporary coverage after excision. Application of cadaveric and pig skin grafts carries a risk of auto-immune response and risk of viral and bacterial diseases transmission, and there are many cultural and religious rejections for use of porcine grafts. There has recently become available an alternative resource of xenograft using acellular fish skin (KerecisTM Omega3 Burn). This has been described as providing an effective, safe, efficient skin substitute, free of the risk of transmission of viral disease and auto-immune reaction risk.

Methods

Ten patients having split-thickness skin grafting for burn injury were treated with the fish skin xenografts. All patients were over 18 years of age. All donor sites were harvested at a depth of 8/1000th of an inch. After soaking of the fish skin in saline, the fish skin was applied and held in place with a secondary dressing. The first dressing change to the donor site after surgery was performed at seven days and then was performed every three days thereafter until fully healed. The symptoms and signs of infection were assessed, and pain was assessed using a Verbal rating Score of 0-10 at each dressing change. Days to 100% epithelialisation were recorded.

Lessons Learned:

- Healing using the fish skin product appeared to be at least as good if not better than other dressings
- Potential non-opiate analgesic effect due to reduced inflammation.

% of total patients (n=10)

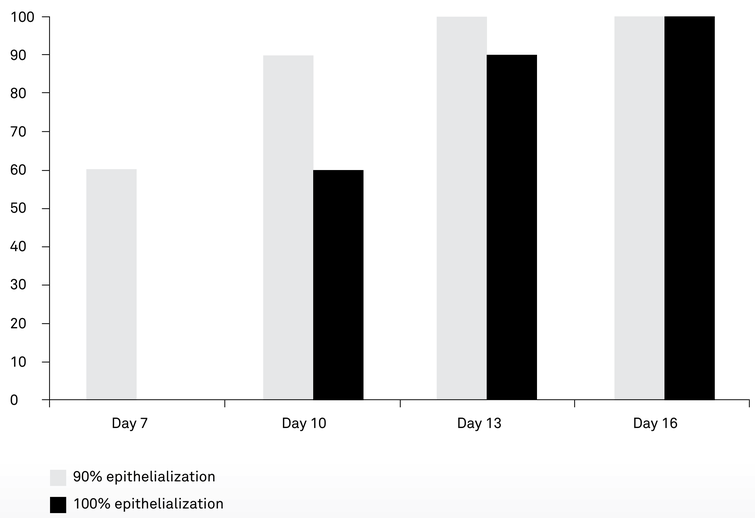

Type of study	Case Series	RCT	RCT	RCT	RCT	RCT	RCT	RCT	RCT	RCT	RCT	RCT	RCT
Reference	Khurshid et al. 2018	Markl et al. 2010	Markl et al. 2010	Bailey et al. 2011 and Assadian et al. 2013	Assadian et al. 2013 - USA	Solanki et al. 2012 and Brolmann et al. 2013	Kaiser et al. 2013	Solanki et al. 2012	Brolmann et al. 2013 and Markl et al. 2010	Brolmann et al. 2013	Brolmann et al. 2013	Brolmann et al. 2013	Brolmann et al. 2013
Number of patients	10	26	20	27	17	57	15	8	74	47	45	50	49
Type	Fish skin graft	Foam dressing	Dressing	Silver dressing	Dressing	Dressing	Gauze	Dressing	Silicone dressing	Dressing	Alginate dressing	Gauze	Semiperme-able film
Brand name	Kerecis™ Omega3 by Kerecis	Biatain® Ibu by Coloplast	Suprathel® by Polymedics	Aquacel® Ag Extra™ Hydrofiber® by ConvaTec®	Altrazeal™ by Uluru	Duoderm® by ConvaTec®	Bactigras® by Smith & Nephew	Biobrain® by Smith & Nephew	Mepitel® by Molnlycke	Aquacel®by ConvaTec	Kaltostat® by ConvaTec	Adaptic® by Acelity or Jelonet® by Smith & Nephew	Tegaderm® by 3M
Time healing (Mean number of days)	11.5	12.8	12.9	13.0	14.2	15.2	15.4	17.0	21.0	26.0	27.1	27.9	32.9

Results and Discussion

This is the first study to show the effectiveness of using fish skin in acute burns. The experience in our centre for partial thickness burns is promising. The accelerated healing outcomes for the treatment of donor site wounds is also highly encouraging, especially when compared to RCTs on other products. Both a significant analgesic effect noted and the relatively short average times until 100% re-epithelialisation are promising.

Comparison of Omega-3 Rich Fish Skin Dermis and Fetal Bovine Dermis on Deep Partial-Thickness Burns

[1]Randolph Stone II, [1]David Larson, [1]John Wall, [1]Kyle Florell, [1]Hannah Dillon, [2]Skuli Magnusson, [2]Hilmar Kjartansson, [1]Shanmugasundaram Natesan, [1]Robert Christy

[1]US Army Institute of Surgical Research, JBSA Fort Sam Houston, TX, [2]Kerecis, Reykjavik, Iceland

Introduction

Burn injuries can be caused by exposure to a wide variety of sources including heat, electricity, radiation, chemical agents, and friction. Split thickness skin grafts are currently the gold standard, which are associated with donor site morbidity and may be impossible in cases where there is no available donor skin. The paucity of donor sites in patients with burns involving large total body surface areas highlights the need for better acellular dermal matrix (ADM) products that can achieve early and complete coverage while retaining normal skin function. A variety of ADMs have been tested on burn wounds resulting in limited success due to poor integration and insufficient revascularization of the product (1-4).

Objective/Hypothesis

Objective: Conduct a side by side comparison of ADMs sourced from two different animals in a preclinical porcine deep partial-thickness (DPT) burn model.

Hypothesis: We hypothesize the omega-3 rich fish skin dermis will integrate, re-vascularize, and lead to better wound healing outcomes than fetal bovine dermis.

Methods

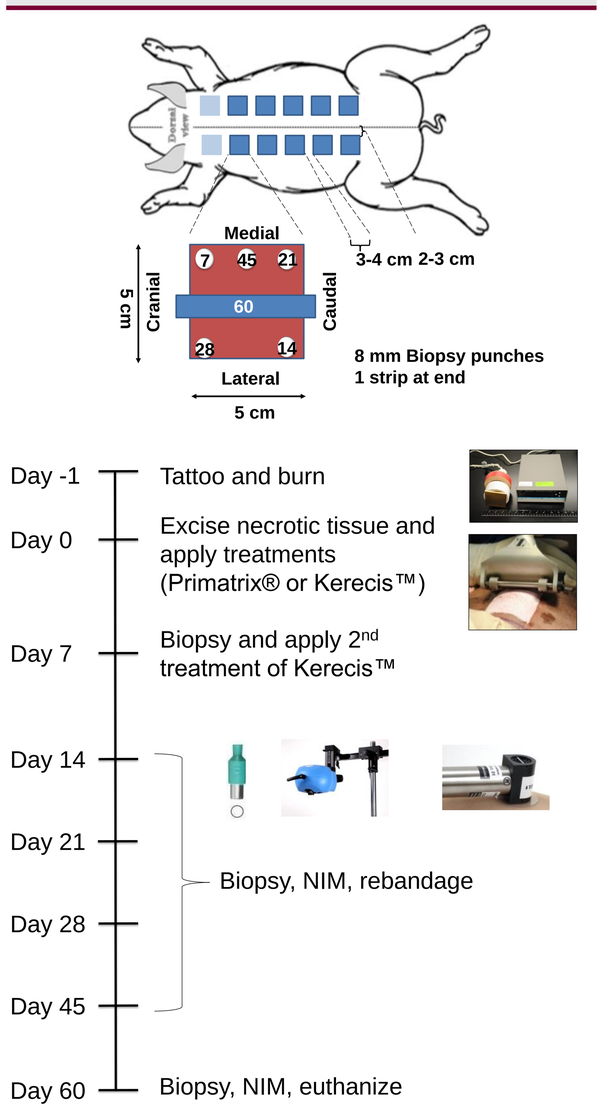

Figure 1 Pig schematic and timeline
Twenty-four 5x5 cm DPT burn wounds were created on the dorsum of anesthetized Yorkshire pigs. The schematic indicates the timeline and methods utilized throughout the study. NIM = non-invasive measurements to include digital and laser speckle imaging, TransEpidermal Water Loss (TEWL), and hydration readings.

Results

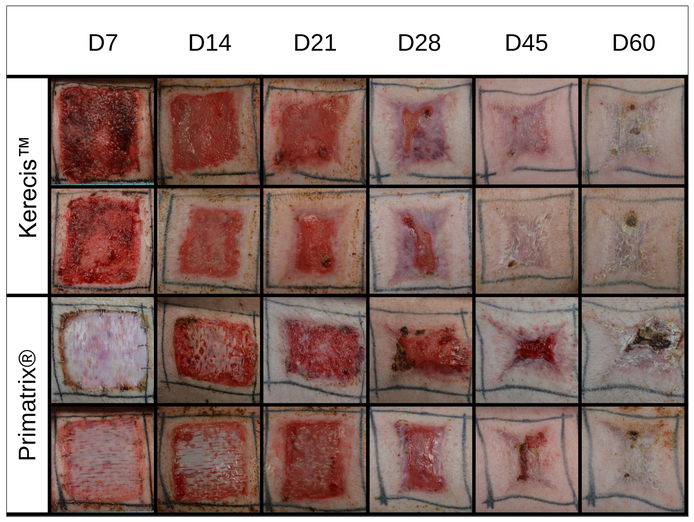

Figure 2: Representative digital images
Digital images were captured of all wounds during the 60 day study.

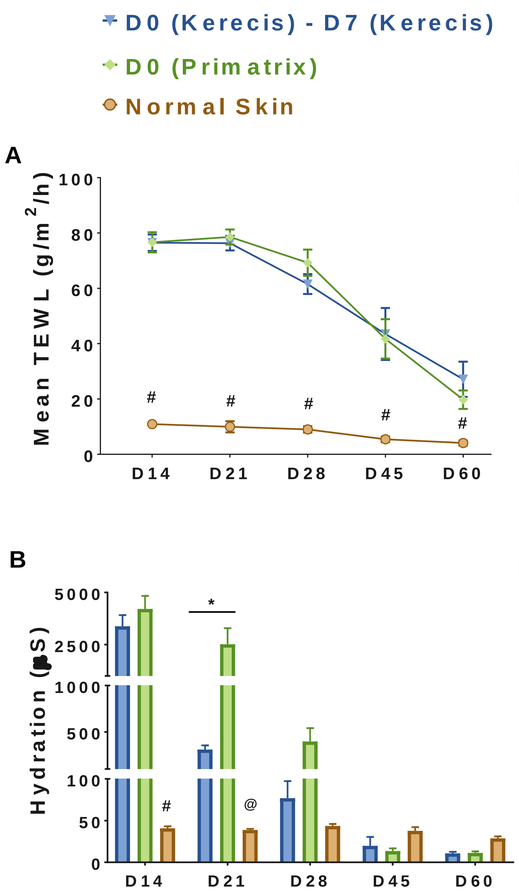

Figure 3: Skin barrier function measurements
A) TransEpidermal Water Loss (TEWL) measures the barrier properties of the epidermal layer of skin. Three measurements were obtained for each wound at each time point and averaged. (# = p<0.05 normal vs. treatment groups).

B) The hydration measures the water content of the wounds. Five measurements were obtained for each wound at each time point and averaged. (* = p<0.001 comparing treatments; # = p<0.001 normal vs. treatment groups; @ = p<0.001 normal vs. Primatrix®).

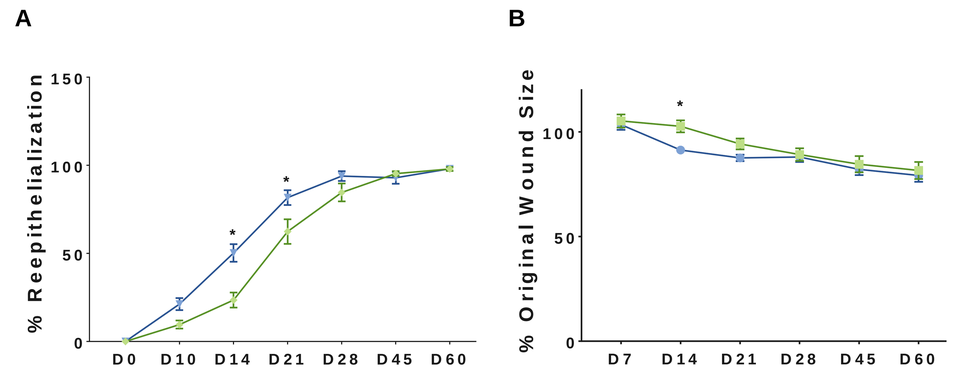

Figure 4: Wound closure and contraction
A) Re-epithelialization was calculated by tracing the leading edge of the epidermis and comparing to total wound size. **B)** Wound contraction was calculated by tracing the tattoos, comparing to the initial wound size, and normalizing to the growth of each animal (* = p<0.05 comparing treatments).



Figure 5: Laser Speckle Imaging
A) Digital day 14 and laser speckle images (LSI) indicating higher perfusion (red) in the healing wounds. By day 60, the perfusion within the wound has returned to baseline levels indicated by the blue coloring.

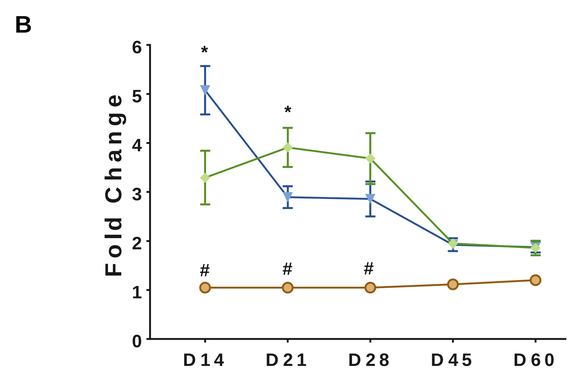

B) Quantitation of LSI measurements represented as a fold change above the normal perfusion around each wound (* = p<0.05 comparing treatments; # = p<0.05 normal vs. other groups).

Acknowledgements

RC is an employee of the U.S. government and this work was prepared as part of his official duty. This research was supported in part by an appointment to the Postgraduate Research Participation Program at the U.S. Army Institute of Surgical Research administered by the Oak Ridge Institute for Science and Education through an interagency agreement between the U.S. Department of Energy and USAISR. This research was funded by the U.S. Army Medical Research and Materiel Command and Military Burn Research Program.

References

1. Rowan et al. 2015. Critical Care. Burn wound healing and treatment: review and advancements.
2. Zuo et al. 2017. Plastic and Reconstructive Surgery. Important developments in burn care.
3. Chen et al. 2013. Int J clin Exp Pathol. The effect of porcine ADM to improve the burn wound healing.
4. Wainwright et al. 2011. Aestet Surg J. Acelullar dermal matrix in the management of the burn patient.

Conclusions

- Kerecis™ treatment of DPT burn wounds resulted in faster re-epithelialization when compared to a commercial comparator (Primatrix®)
- No differences in TEWL measurements were detected between Kerecis™ and Primatrix®
- Hydration levels of the Kerecis™ treatment correlate to re-epithelialization and return to normal skin levels by day 21
- LSI indicated that Kerecis™ established a perfused wound bed faster (by day 21) than Primatrix®
- Overall, the long term healing was similar for both products

Statement

Research was conducted in compliance with the Animal Welfare Act, the implementing Animal Welfare Regulations, and the principles of the Guide for the Care and Use of Laboratory Animals, National Research Council. The facility's Institutional Animal Care and Use Committee approved all research conducted in this study. The facility where this research was conducted is fully accredited by AAALAC International.

Omega-3 Rich Fish Skin Grafts Reduce Donor Skin Requirements for Full-Thickness Burns

[1]Randolph Stone II, [1]David Larson, [1]John Wall, [1]Kyle Florell, [1]Hannah Dillon, [2]Skuli Magnusson, [2]Hilmar Kjartansson, [1]Shanmugasundaram Natesan, [1]Robert Christy

[1]US Army Institute of Surgical Research, JBSA Fort Sam Houston, TX, [2]Kerecis, Reykjavik, Iceland

Introduction

Large total body surface area burns pose significant therapeutic challenges. Clinically, the extent and depth of burn injury may mandate the temporary use of cadaver skin (allograft) to protect the wound and allow formation of granulation tissue while split thickness skin grafts (STSG) are serially harvested from the same donor areas. However, allografts are not always available and have high cost associated with them, thus the interest in identifying lower cost, readily available products that serve the same function. A second function of allografts is to protect a highly meshed STSG (mSTSG) from desiccation and shearing (1-2).

Objectives/Hypothesis

Objectives: Evaluate omega-3 rich fish skin graft as a temporary covering to prepare the wound bed for mSTSG application and as protection over a highly meshed STSG.

Hypothesis: We hypothesize the omega-3 rich fish skin graft will enhance granulation tissue formation that promotes successful autografting and reduce donor skin requirements by promoting quicker healing of widely meshed autografts.

Methods

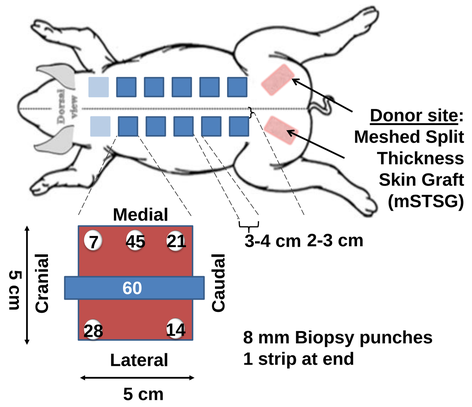

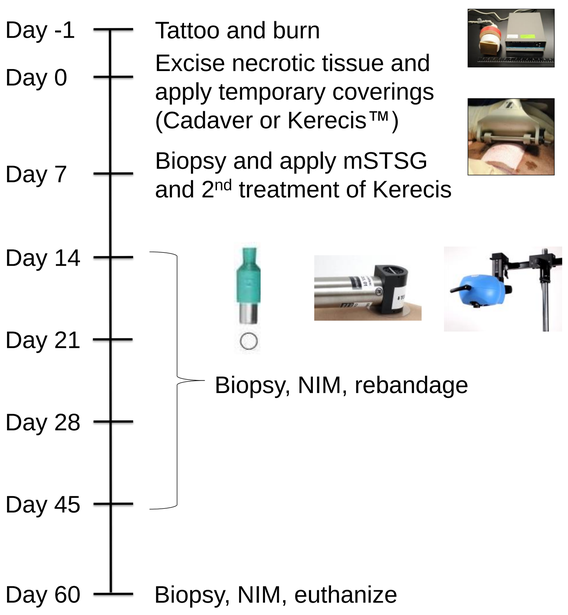

Figure 1: Pig schematic and timeline
Thirty-six 5x5 cm FT burn wounds were created on the dorsum of anesthetized Yorkshire pigs. The schematic indicates the timeline and methods utilized throughout the study. NIM = non-invasive measurements to include digital and laser speckle imaging, TransEpidermal Water Loss (TEWL), and hydration readings. mSTSG = meshed split thickness skin graft

Results

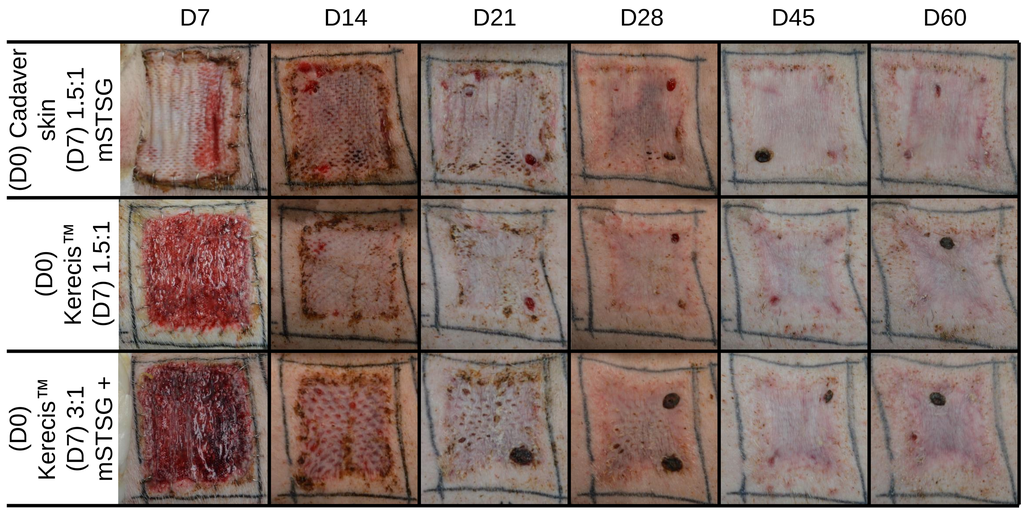

Figure 2: Representative digital images
Digital images were captured of all wounds during the 60 day study.

EXPERIMENTAL GROUPS

1) D0 (Cadaver skin) - D7 (1.5:1 mSTSG)
2) D0 (Kerecis) - D7 (1.5:1 mSTSG)
3) D0 (Kerecis) - D7 (3:1 mSTSG/Kerecis)
4) Normal Skin

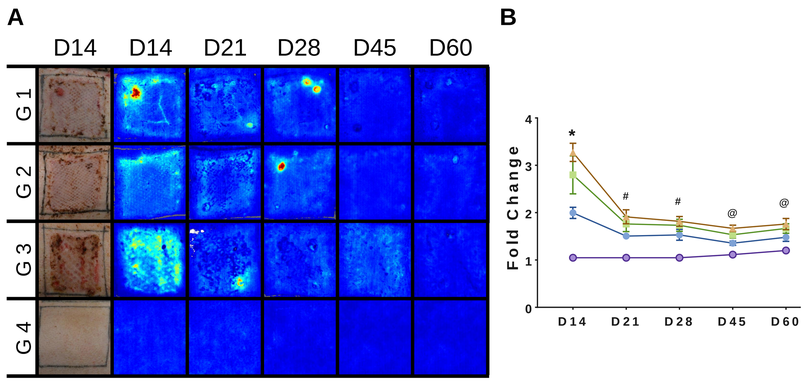

Figure 4: Laser Speckle Imaging
A) Digital day 14 and laser speckle images (LSI) indicating higher perfusion (red/yellow) in the healing wounds. By day 60, the perfusion within the wound has returned to baseline levels indicated by the blue coloring.
B) Quantitation of LSI measurements represented as a fold change above the normal perfusion around each wound (* = p<0.05 between all groups; # = p<0.05 Kerecis™ treated vs. normal; @ = p<0.05 3:1 mSTSG + Kerecis™ (Group 3) vs. normal).

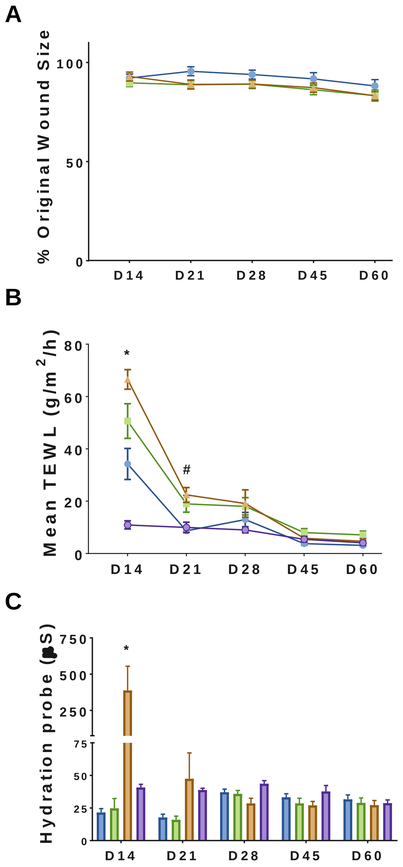

Figure 3: Wound contraction and skin barrier functional measurements
A) Wound contraction was calculated by tracing the tattoos, comparing to the initial wound size, and normalizing to the growth of each animal.
B) TransEpidermal Water Loss (TEWL) measures the barrier properties of the epidermal layer of skin. Three measurements were obtained for each wound at each time point and averaged (* = p<0.05 3:1 mSTSG + Kerecis™ (Group 3) vs. other groups; # = p<0.05 for 3:1 mSTSG + Kerecis™ (Group 3) vs. normal).
C) The hydration measures the water content of the wounds. Five measurements were obtained for each wound at each time point and averaged (* = p<0.05 3:1 mSTSG + Kerecis™ (Group 3) vs. other groups).

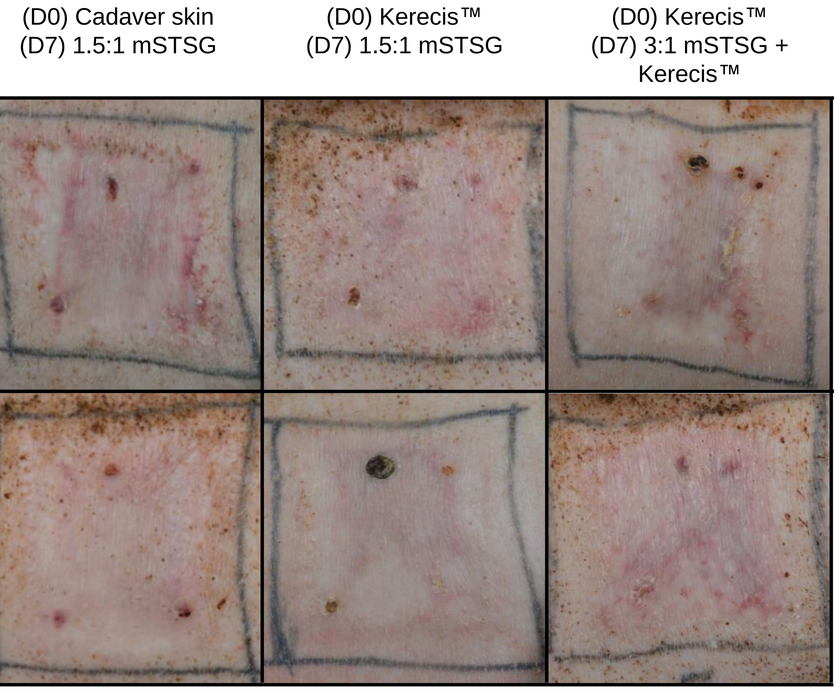

Figure 5: Day 60 representative digital images
No obvious meshed pattern scarring is present at the day 60 final time point.

Conclusions

- Kerecis™ product created a granulated wound bed that was receptive to application of a mSTSG
- FT burn wounds treated with Kerecis™ had similar outcome measures (contraction, TEWL, conductance, blood perfusion) compared to cadaver skin treated wounds
- 3:1 mSTSG + Kerecis™ resulted in similar healing with the wounds treated with 1.5:1 mSTSG
  - **This means less graft (~1/2) was necessary to result in similar healing without any meshed pattern being exhibited**

Acknowledgements

RC is an employee of the U.S. government and this work was prepared as part of his official duty. This research was supported in part by an appointment to the Postgraduate Research Participation Program at the U.S. Army Institute of Surgical Research administered by the Oak Ridge Institute for Science and Education through an interagency agreement between the U.S. Department of Energy and USAISR. This research was funded by the U.S. Army Medical Research and Materiel Command and Military Burn Research Program.

References

1. Rowan et al. 2015. Critical Care. Burn wound healing and treatment: review and advancements.
2. Zuo et al. 2017. Plastic and Reconstructive Surgery. Important developments in burn care.

Statement

Research was conducted in compliance with the Animal Welfare Act, the implementing Animal Welfare Regulations, and the principles of the Guide for the Care and Use of Laboratory Animals, National Research Council. The facility's Institutional Animal Care and Use Committee approved all research conducted in this study. The facility where this research was conducted is fully accredited by AAALAC International.

KERECIS

Distributed by:

PolyMedics Innovations Inc.

8681 Highway 92, Suite 308
Woodstock, GA 30189

Phone +1 646-604-2771
Fax +1 646-350-3129
E-mail info@poly-medics.com

PolyMedics Innovations GmbH

Heerweg 15
73770 Denkendorf I Germany

Phone +49 711 719 500-0
Fax +49 (0)711 719 500-10
E-mail info@polymedics.de

www.poly-medics.com

Key Benefits

- Zero viral transmission risk
- Accelerated wound healing rate
- Supports vascularization
- 3 Year shelf life (5 year pending)
- Omega3 natural bacterial barrier
- Tolerant of wound be environment
- Superior hemostatic properties through platelet binding
- High fibroblast ingrowth and attachment
- Recruits and Supports In-growth of Stem Cells
- Ready for application in 30 seconds